KOREAN SOCIETY OF ULTRASOUND IN MEDICINE

KSUM

KSUM HYBRID CONGRESS 2021

ONLINE & ONSITE

The 52nd Annual Congress of Korean Society of Ultrasound in Medicine

May 13 (Thu) – 15 (Sat), 2021 | Coex, Seoul, Korea

Case of the Day

Answer Sheet

CASE 1

- 50/M
- Incidentally detected hepatic abnormality

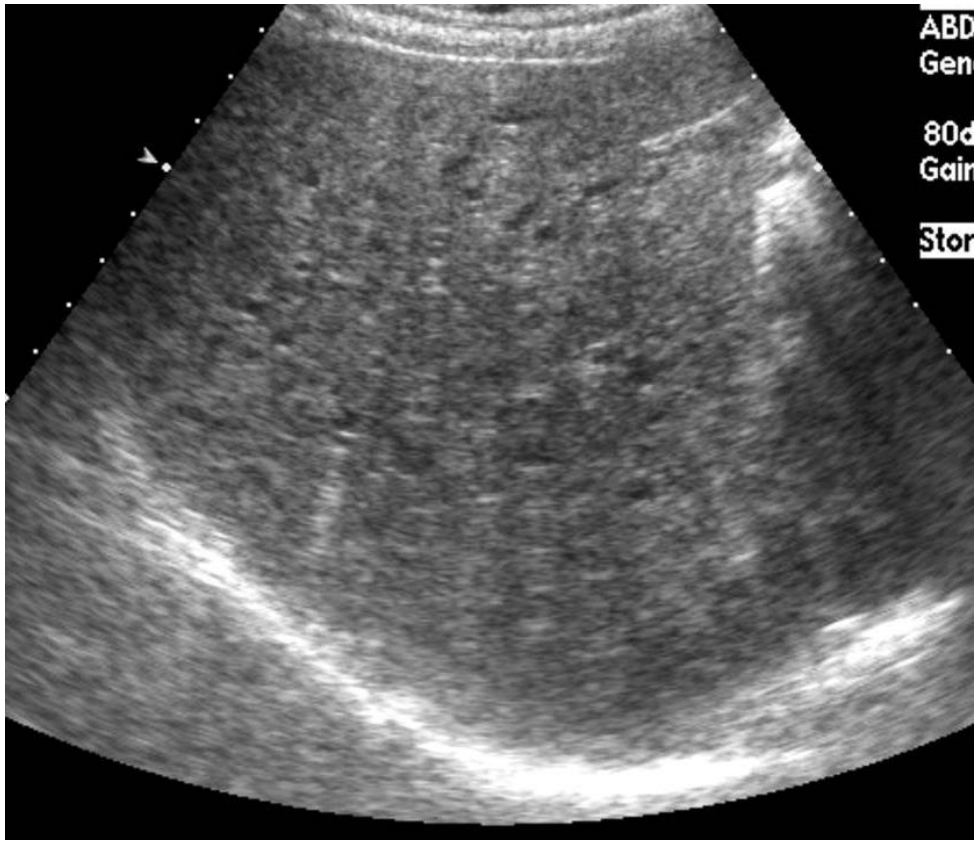

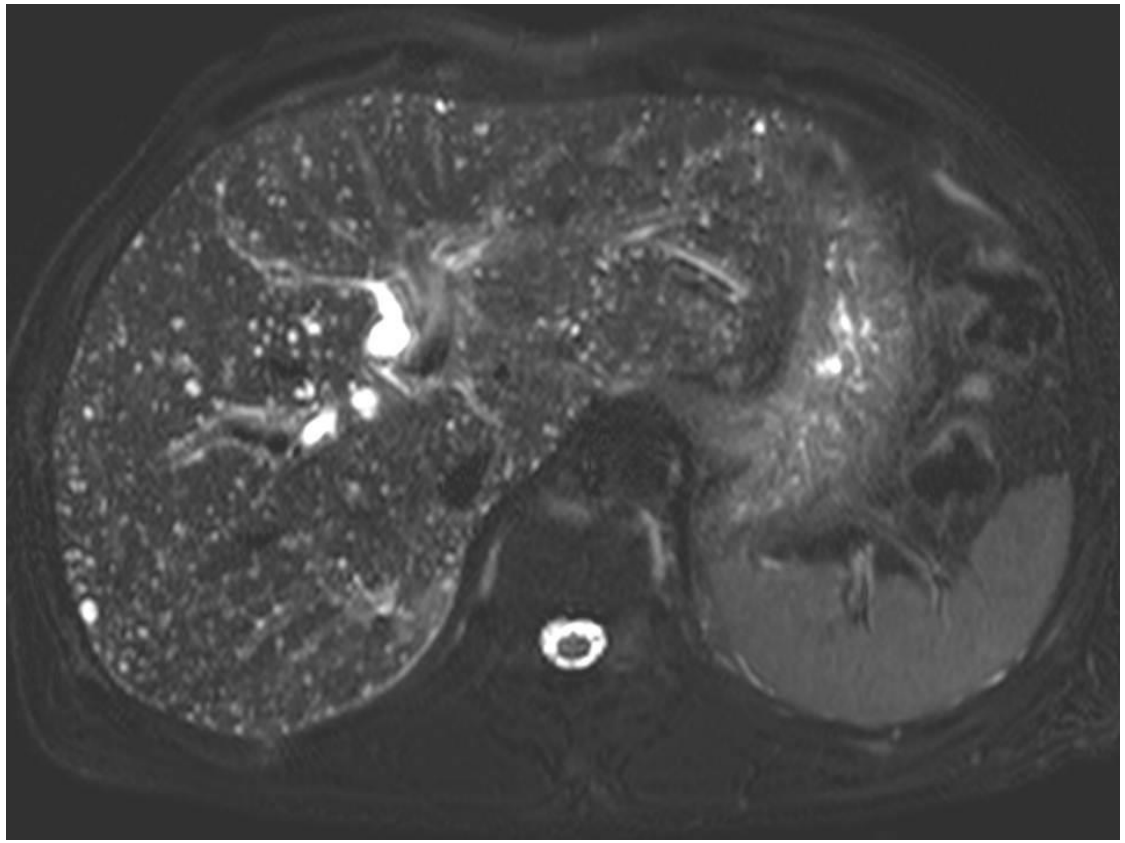

CASE 1

1. What is your diagnosis?

① Lymphoma
② Liver cirrhosis
③ Microabscesses
④ Miliary metastasis
⑤ Von Meyenburg complex **Answer (1 point)**

CASE 1

Biliary hamartoma (von Meyenburg complex)

- A rare cause of multiple benign hepatic lesions
- Multiple small round or irregular lesions throughout the liver, with nearly uniform size, up to 15mm
- US
  - Tiny individual hamartomas cannot be resolved and are instead interpreted as diffuse heterogeneous liver echotexture. Larger hamartomas (>10 mm) may appear anechoic and comet-tail artifact may be seen
- CT/MR
  - Hypoattenuating at CT and bright SI on T2WI of MRI without contrast enhancement

CASE 2

- 64/F
- Abdominal pain

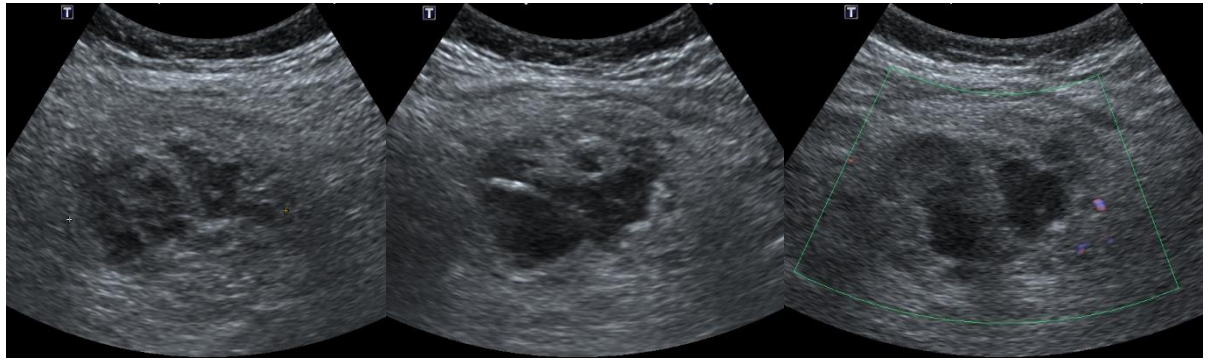

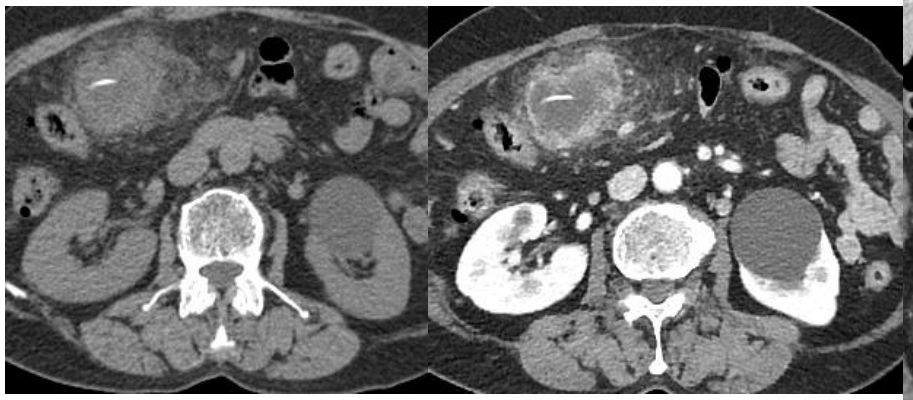

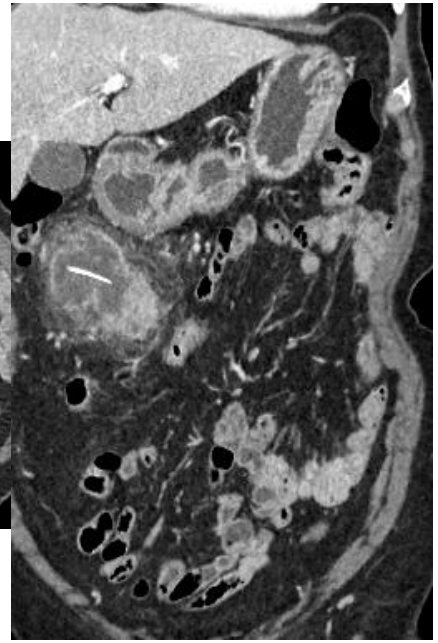

CASE 2

2. What is your diagnosis?

① Metastasis
② Anisakiasis
③ Actinomycosis **Answer (1 point)**
④ Neuroendocrine tumor
⑤ Tuberculous peritonitis (**0.5 points)**

CASE 2

Actinomycosis

- Occurrence by after the disruption of the intestinal mucosal integrity
- PHx of surgery, penetrating trauma and other acute inflammations
- Extension across fascial and connective tissue planes with aggressive infiltration
- CT
  - Concentric wall thickening of adjacent bowel and cystic or solid mass
  - Surrounding prominent inflammatory infiltration
  - Strong enhancement of solid portion and surrounding soft-tissue stranding
- Mimicking malignancy due to invasive nature
  - Rare regional LAP and minimal or absent ascites
  - Unlikely spreading to entire peritoneal cavity despite aggressive infiltration

CASE 3

- 62/F
- Incidentally detected pancreatic mass

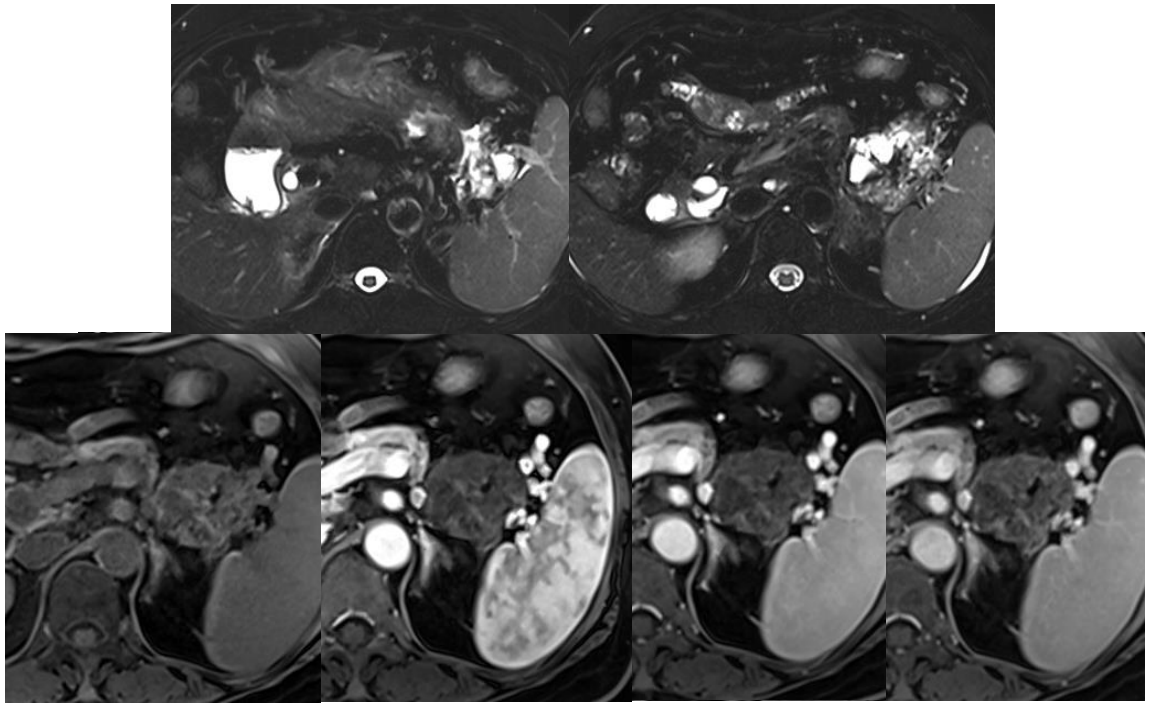

CASE 3

3. What is your diagnosis?

① Metastasis
② Osteosarcoma
③ Calcified granuloma
④ Acinar cell carcinoma
⑤ Solid pseudopapillary tumor **Answer (1 point)**

CASE 3

Solid pseudopapillary tumor

- Low malignant potential with an excellent prognosis
- Large, slow-growing, well-encapsulated
- Tail(m/c), surrounding structures
- Internal hemorrhagic and cystic degeneration is the hallmark of SPT
    - Fragile vascular network of tumor
- 10-18% of cases : fluid-fluid or fluid-debris level (hemorrhagic cyst)
- Peripheral calcification : 30%
- Gradual heterogeneous enhancement

CASE 4

- 27/F
- Incidentally detected right inguinal mass

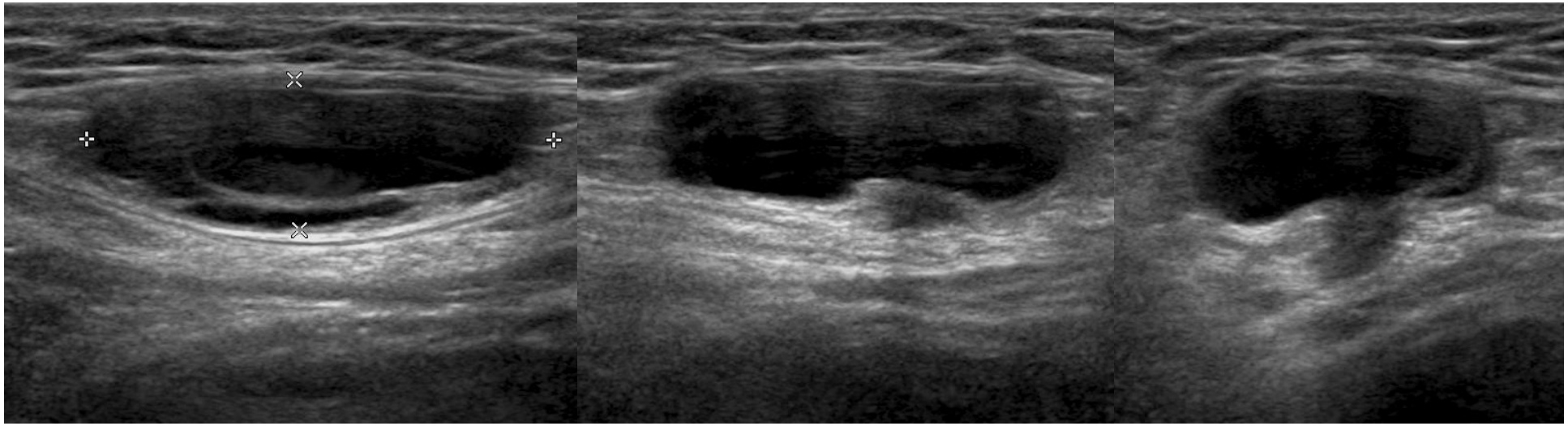

CASE 4

4. What is your diagnosis?

① Canal of Nuck **(0.5 points)**
② Mesothelial cyst **Answer (1 point)**
③ Varicosities
④ Lymphangioma
⑤ Lipoma

CASE 4

Round ligament mesothelial cysts

- Right groin of middle-aged women
- Fusiform-shaped cystic mass without peristalsis
- Connected to the stalk-like structure (arrows)
- Medial to that of usual inguinal hernia (Clinical Imaging 2016; 949-955)

CASE 5

- 73/M
- Foot swelling (a year ago)

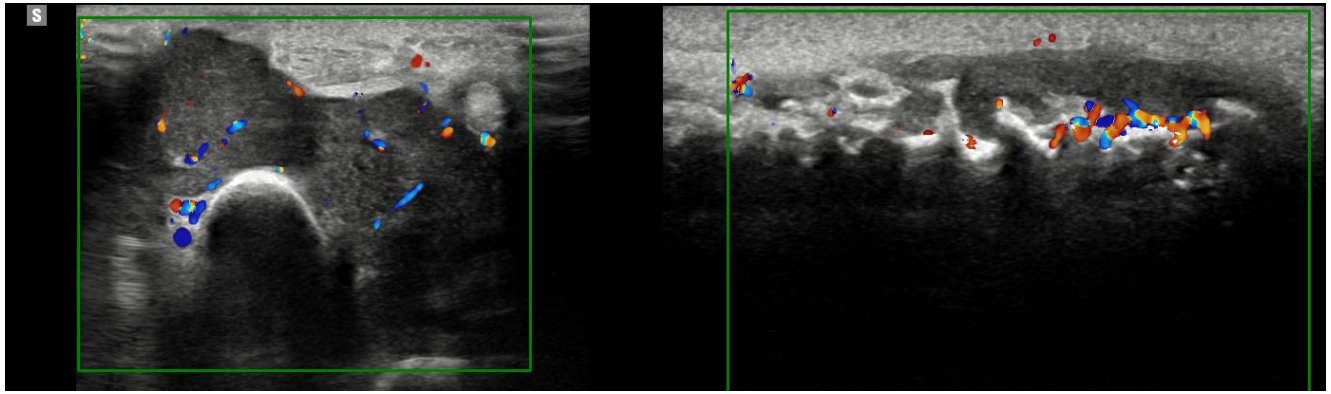

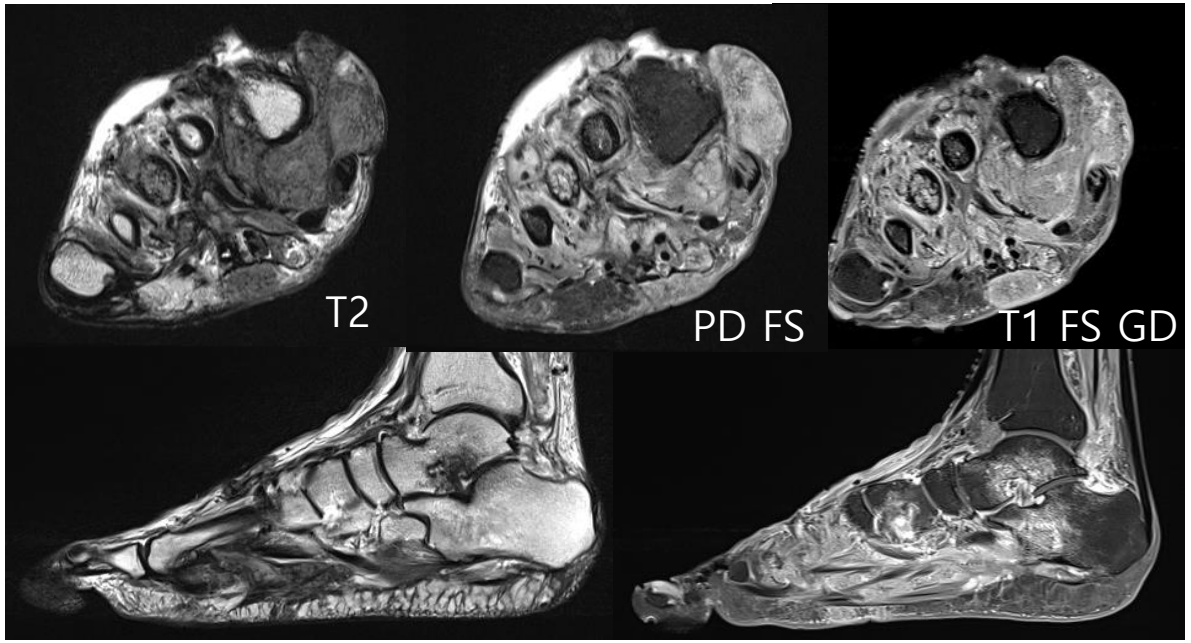

CASE 5

5. What is your diagnosis?

① Amyloidosis
② Fibromatosis
③ Actinomycosis **Answer (1 point)**
④ Rheumatoid nodules
⑤ Tenosynovial giant cell tumor

CASE 5

Actinomycosis of the foot

- Actinomycosis is an indolent, slowly progressive, suppurative infection caused by gram-positive branching bacteria of the genus *Actinomyces.*
- Male predominance
- Trauma history
- Painless swelling

Radiologic Findings

- Usually as an extensive soft tissue mass like lesion with vascularity
- Indistinguishable from malignant soft tissue sarcoma (J Am Col Certif Wound Spec.2009 3;1(3):95-100)

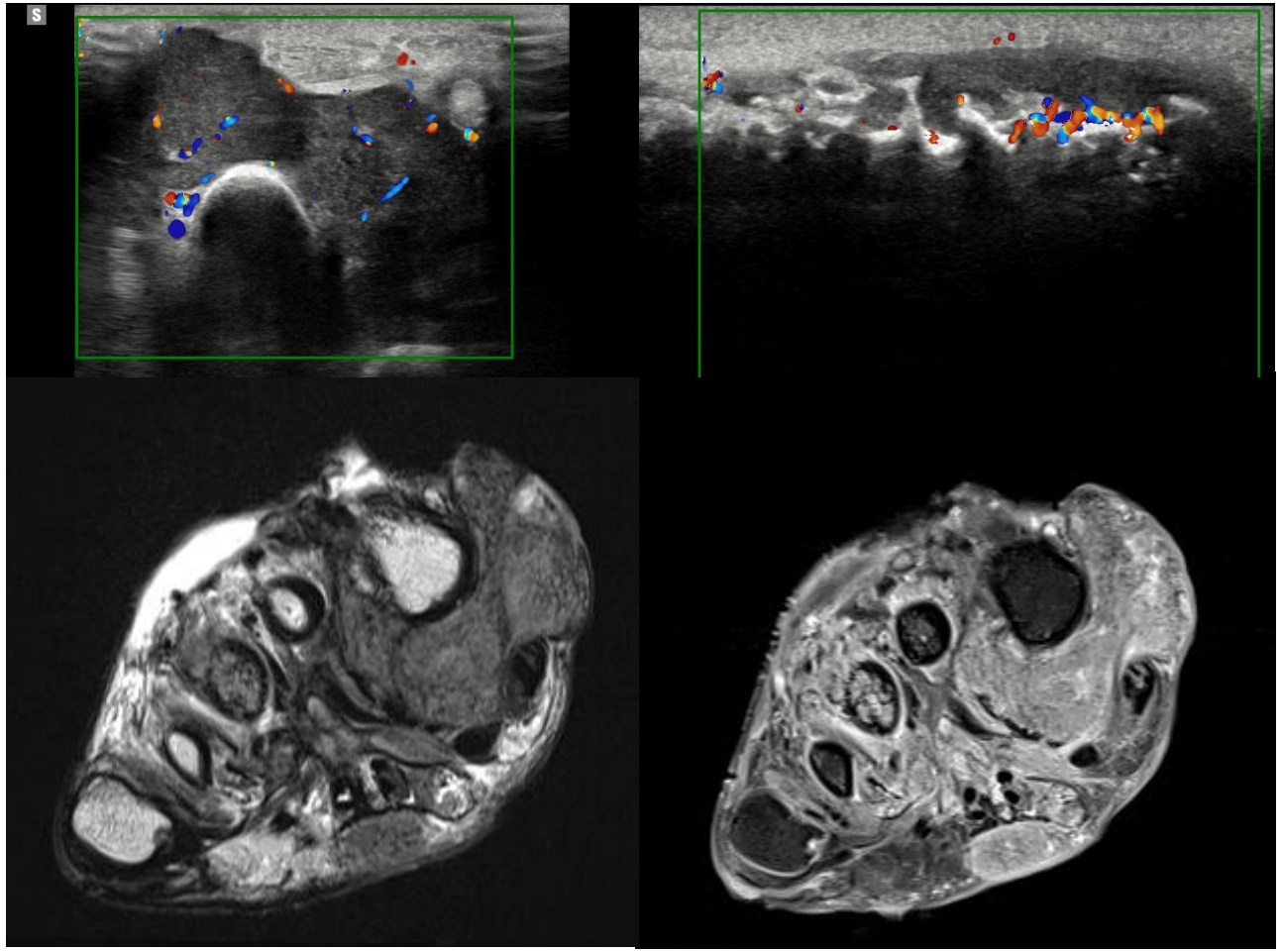

CASE 6

- 55/M
- Bilateral upper arm swelling with fever (2 months ago)

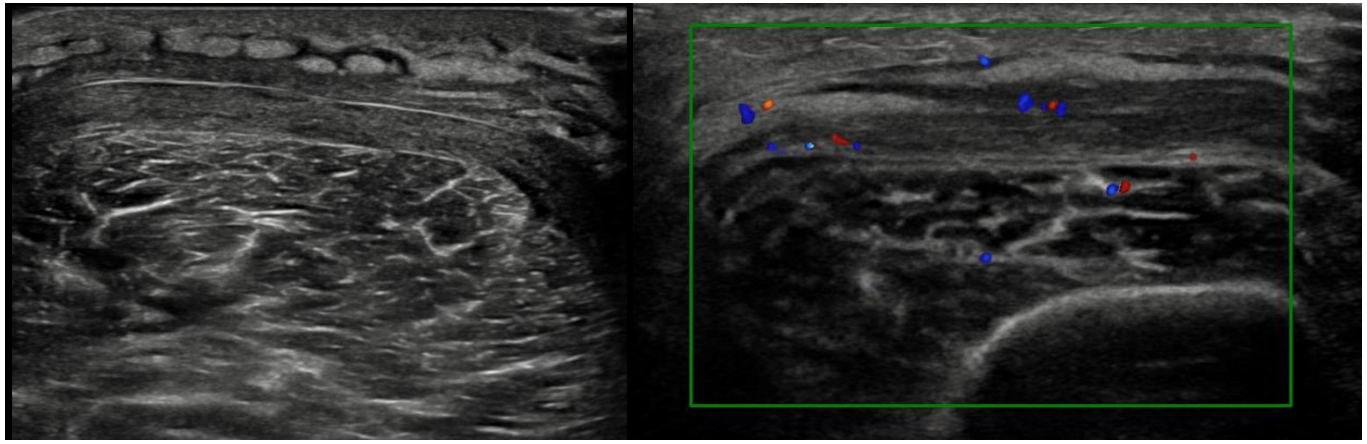

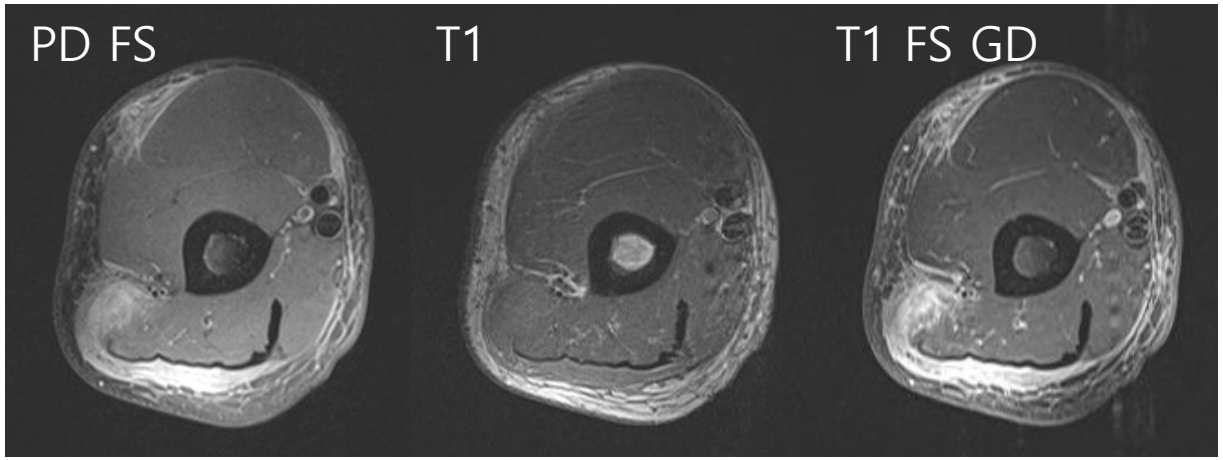

CASE 6

6. What is your diagnosis?

① Lymphoma **Answer (1 point)**
② Sweet syndrome
③ Dermatomyositis
④ Necrotizing fasciitis
⑤ Eosinophilic fasciitis

CASE 6

Primary cutaneous Extranodal NK / T-cell lymphoma

- A group of clonal proliferations of cytotoxic lymphocytes of NK or rarely T-cell types, presenting mainly as tumors or destructive lesions in the nasal cavity, maxillary sinuses or palate
- Extranodal NK/T-cell lymphomas; the skin, testis, lung, or gastrointestinal tract

Radiologic Findings

- Similar to those of cellulitis or fasciitis with vascularity
- Indistinguishable from inflammatory fasciitis or cellulitis (AJR 2010; 195:1355-1360)

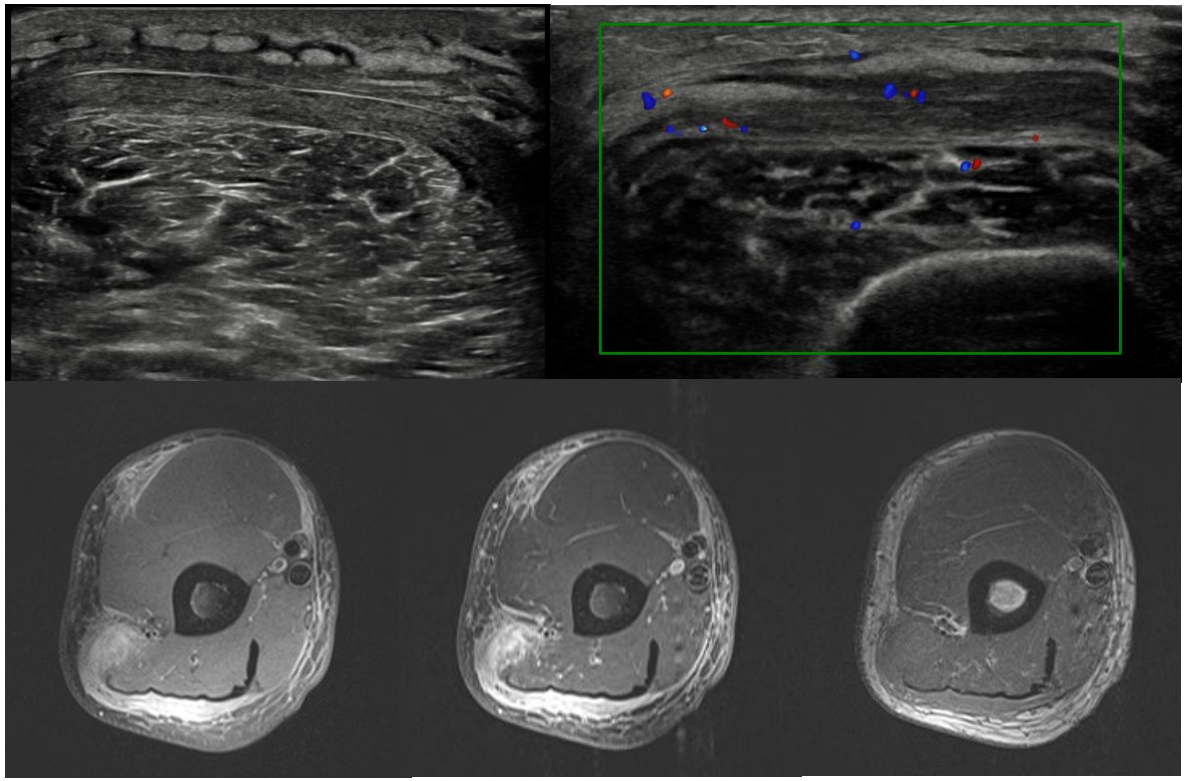

CASE 7

- 39/M
- Right facial mass (onset : 3 years ago)

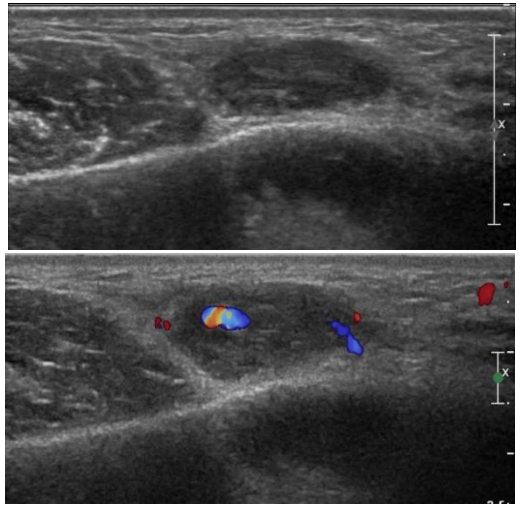

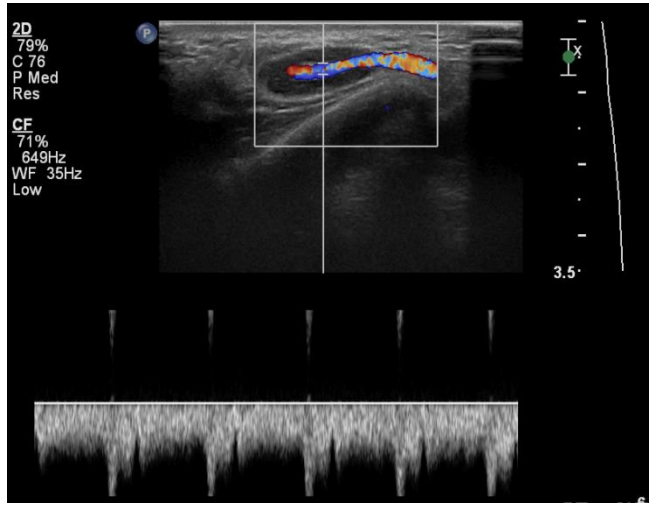

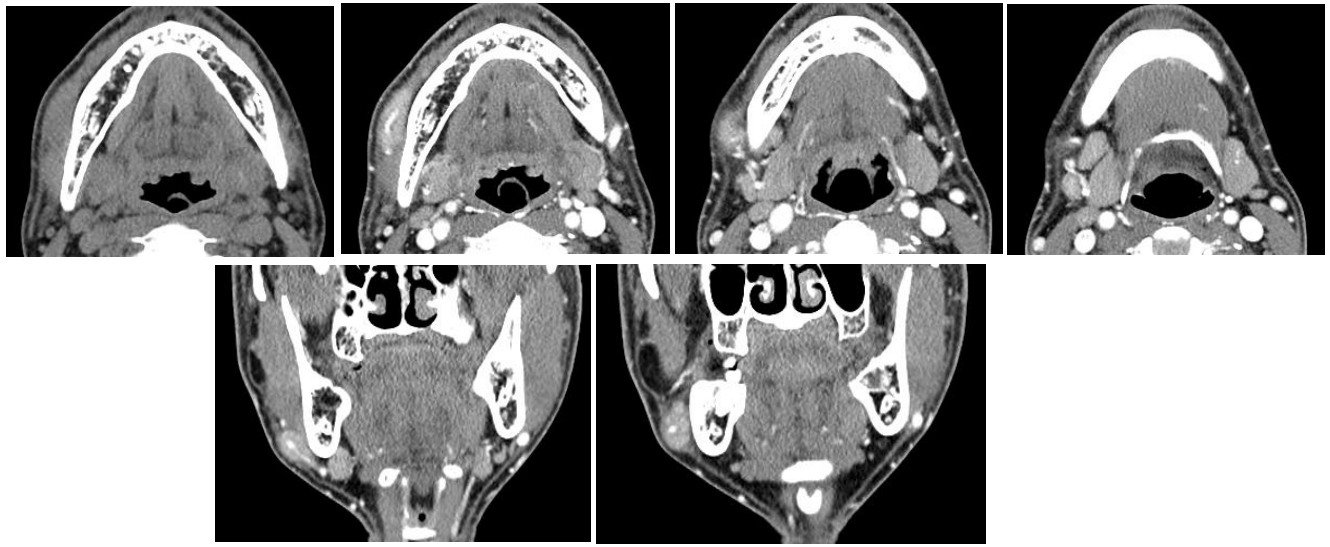

CASE 7

7. What is your diagnosis?

① Hemangioma
② Leiomyoma
③ Lymphoma
④ Kimura disease **Answer (1 point)**
⑤ IgG4-related disease

CASE 7

Kimura disease

- A benign, rare, chronic inflammatory condition
- Typically affects Asian males between 20 and 40 years of age
- Symptom : a painless, slow-growing, subcutaneous nodule usually manifesting on the face or neck with the parotid region being the most common site of involvement

Ultrasonography findings

1) Nodal involvement

- Enlarged lymph nodes with well-defined border and hypoechoic appearance
- Homogeneous internal architecture, non-necrotic and preserved echogenic hilum
- No nodal matting and adjacent soft tissue edema
- Color Doppler : hilar hypervascularity or mixed hilar and peripheral

CASE 7

Ultrasonography findings (Cont.)

2) Subcutaneous/soft tissue involvement

- Well/ill-defined, hypoechoic masses or plaque–like lesions
- Homogeneous or heterogeneous internal architecture
- Hypoechoic area interspersed with hyperechoic areas: wooly appearance
- Color Doppler : arterial and venous follow within lesions

3) Salivary gland involvement

- Focal/diffuse, hyperechoic, heterogeneous parenchymal echo pattern.
- Enlarged intraparotid nodes

CASE 8

- 45/M
- Sudden lump sensation at neck

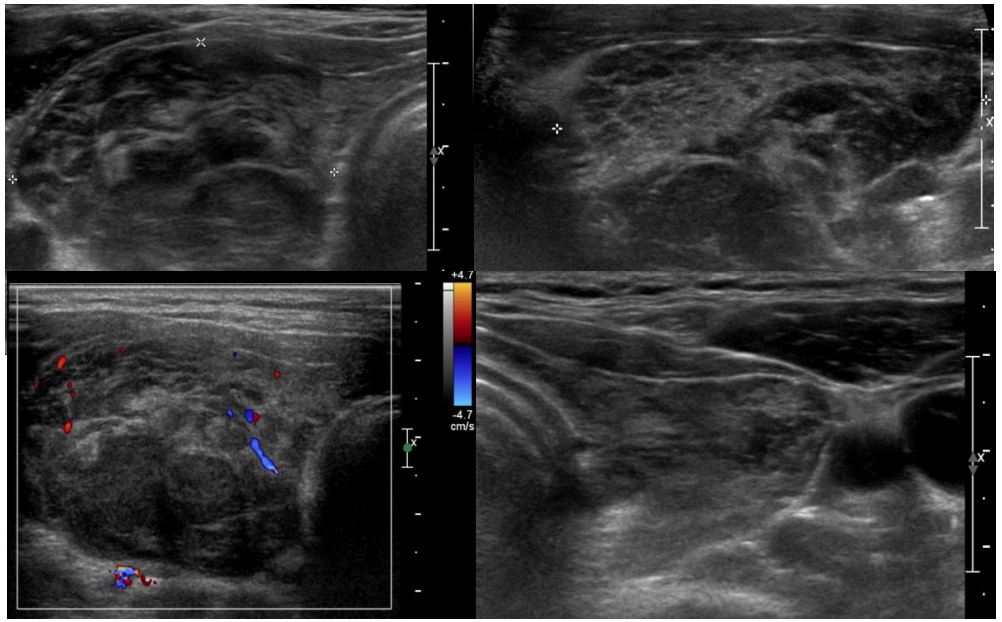

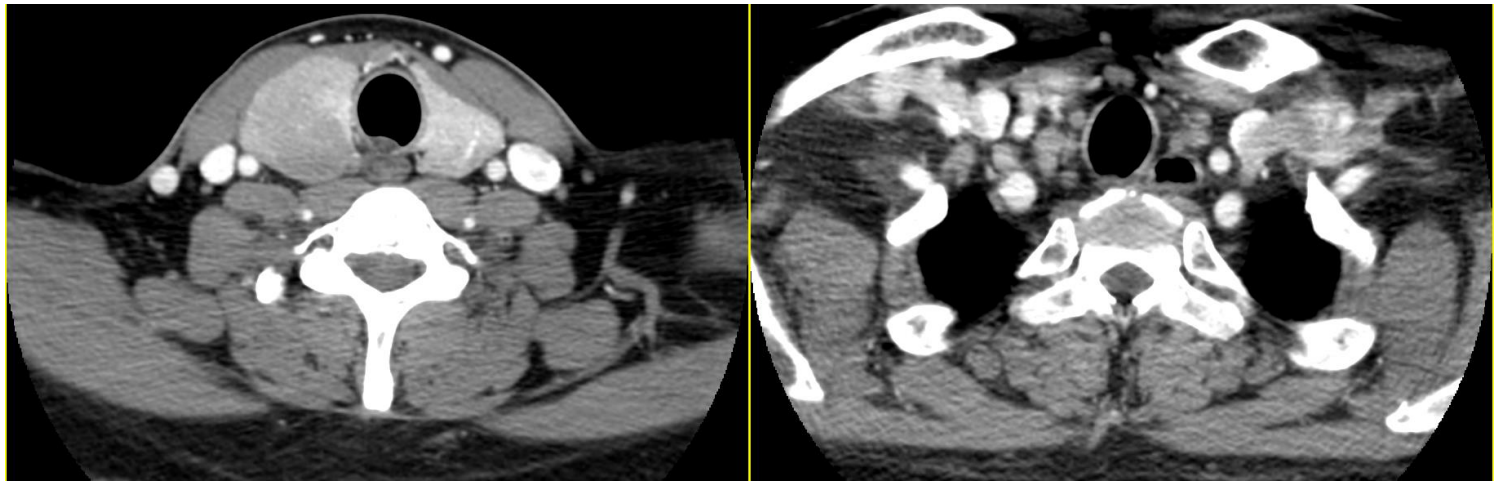

CASE 8

8. What is your diagnosis?

① Thyroid lymphoma **Answer (1 point)**
② Hashimoto thyroiditis **(0.5 points)**
③ Goiter
④ Papillary thyroid carcinoma
⑤ Metastasis

CASE 8

Primary thyroid lymphoma

- Uncommon thyroid malignancy (2.2~5%)
- The etiology is unclear and the major risk factor is Hashimoto's disease
- Clinical presentation :
  - Rapidly enlarging cervical mass with compressive symptoms
  - Cervical lymphadenopathy
- Non-Hodgkin lymphoma of B-cell origin is most common (DLBCL and MALT lymphoma)

CASE 8

- **US**
  - Diffuse, and non-diffuse (nodular) type
  - Goiter, heterogenous echotexture, markedly hypoechogenicity with posterior acoustic enhancement
  - Calcification is rare

- **CT**
  - Homogenous soft-tissue mass, isoattenuating to surrounding muscles
  - Compress normal remnant thyroid and surrounding structure without invasion
  - Cervical lymphadenopathy

CASE 9

- 62/F
- Abnormal finding on mammography

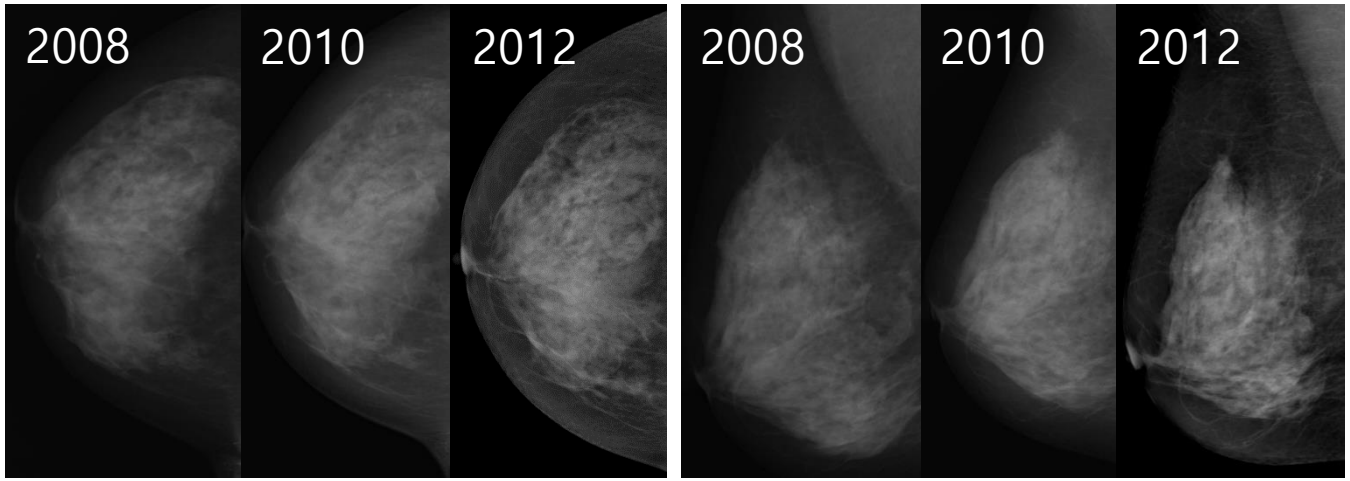

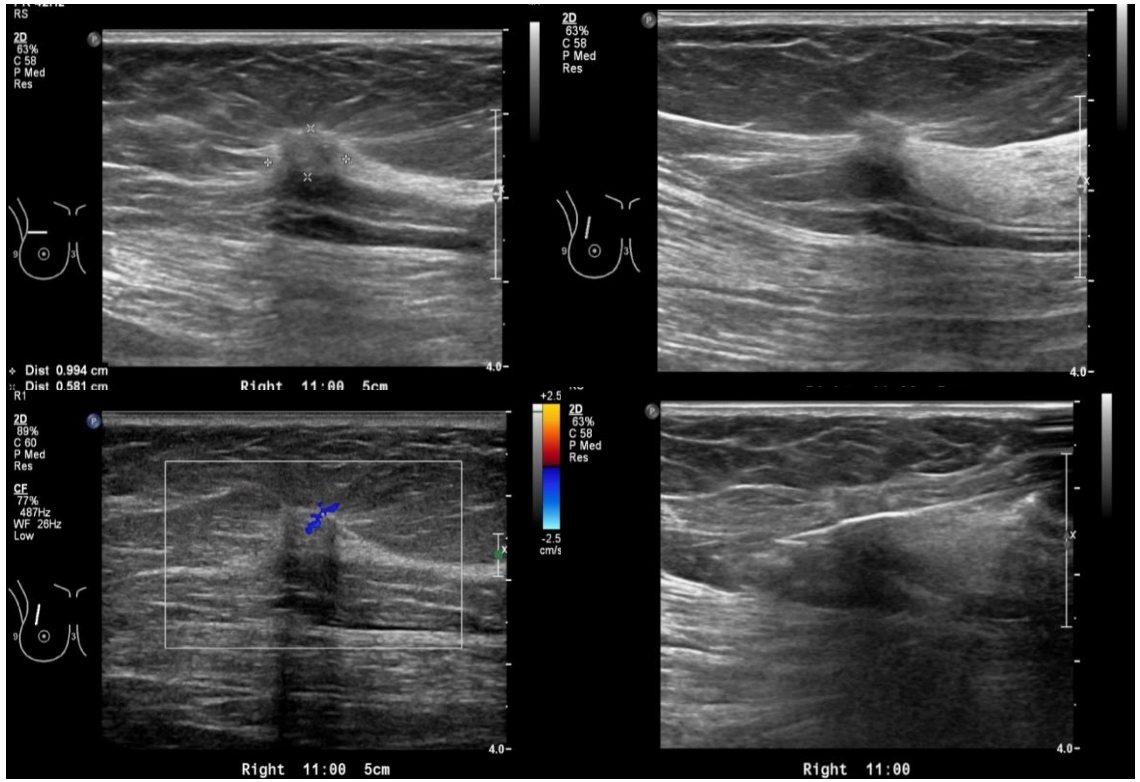

CASE 9

9. What is your diagnosis?

① Radial scar
② DCIS
③ Tubular carcinoma **Answer (1 point)**
④ Invasive ductal carcinoma **(0.5 points)**
⑤ Atypical ductal hyperplasia

CASE 9

Tubular carcinoma

- Subtype of invasive ductal carcinoma
- Rare breast cancer (~1%)
- Pathology : well-differentiated tubular structure
- Very slow growing
  - Non palpable and often found incidentally at screening
- Young female (mean age : 40-49 yrs)

- Imaging finding
  - Small (<1cm), spiculated mass on MMG (with suspicious microcalcification: 8-24 %)
  - Irregular hypoechoic mass with posterior acoustic shadowing on US

CASE 10

- 71/F
- History of Lt. BCS d/t invasive ductal carcinoma, 2 YA

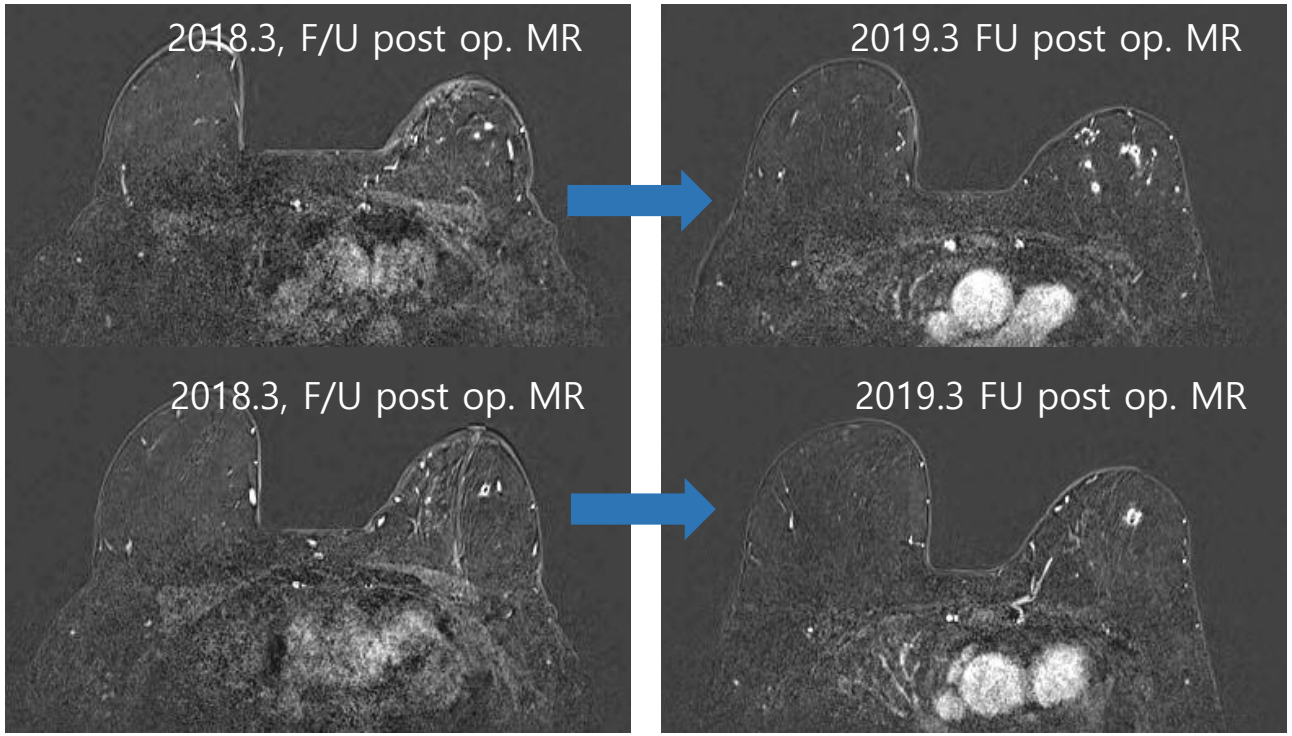

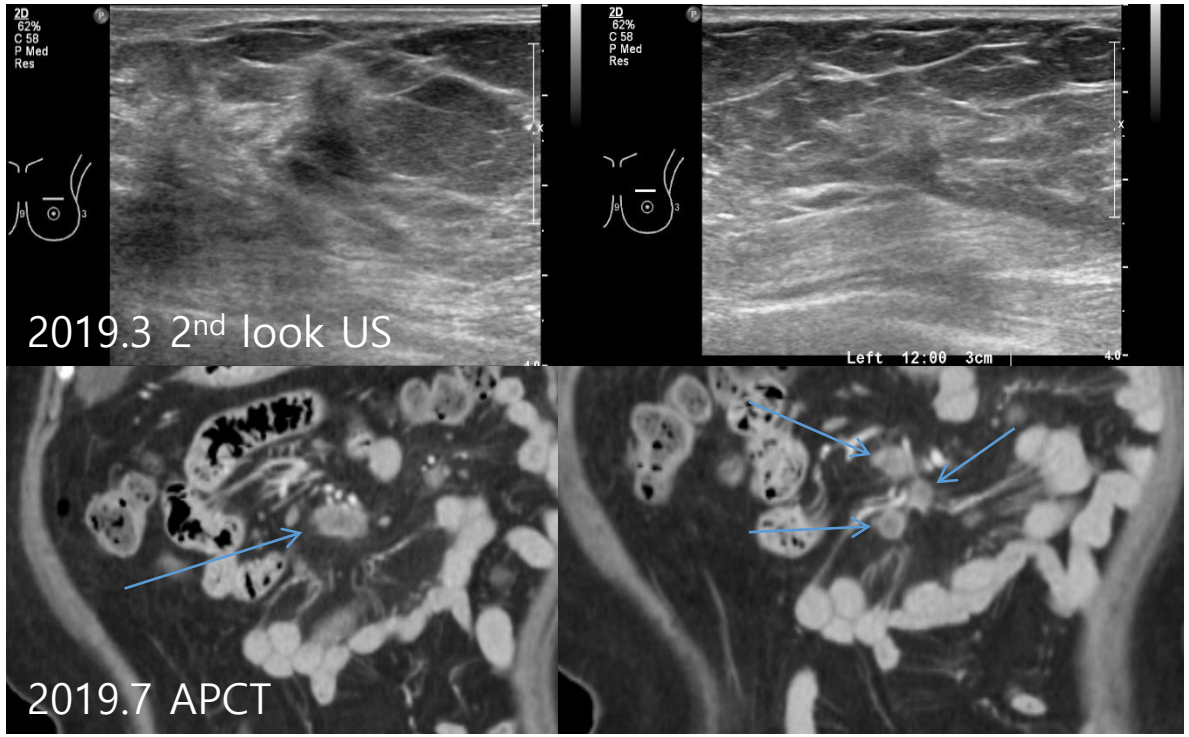

CASE 10

10. What is your diagnosis?

① Papillomatosis
② Metastasis **(0.5 points)**
③ Sclerosing panniculitis **Answer (1 point)**
④ Ipsilateral breast tumor recurrence (IBTR**)** **(0.5 points)**
⑤ Lymphoma

CASE 10

Sclerosing panniculitis involving breast

- On post op. MR, there were multiple rapidly enhancing masses in Lt. breast with interval increased in size and number on 1yr FU
- On gray scale US, there was a 2.3cm irregular ill-defined hypoechoic mass with peripheral halo at Lt. breast 1'o clock direction. There were other multiple small hypoechoic nodules with peripheral halo in left breast.
- On APCT scan, there were enlarged lymph nodes with necrotic change at mesentery.

- The patient underwent mammotome biopsy for breast mass and lymph node biopsy at mesentery, the lesions were confirmed as sclerosing panniculitis

CASE 10

Sclerosing panniculitis

- Rare, idiopathic fibro-inflammatory disorder
- Etiology
  - Unclear, may be found in isolation
  - May be related to autoimmune process, infection, ischemia, trauma, surgery
  - Coexistence with malignancy in 18-69% (including breast cancer, lymphoma)
- CT findings for mesenteritis
  - Misty mesentery
  - Tumoral pseudocapsule
  - Small soft tissue nodules
  - Fat ring sign
  - Retractile mesenteritis

CASE 11

- 1 day/F
- Polyhydramnios on prenatal US

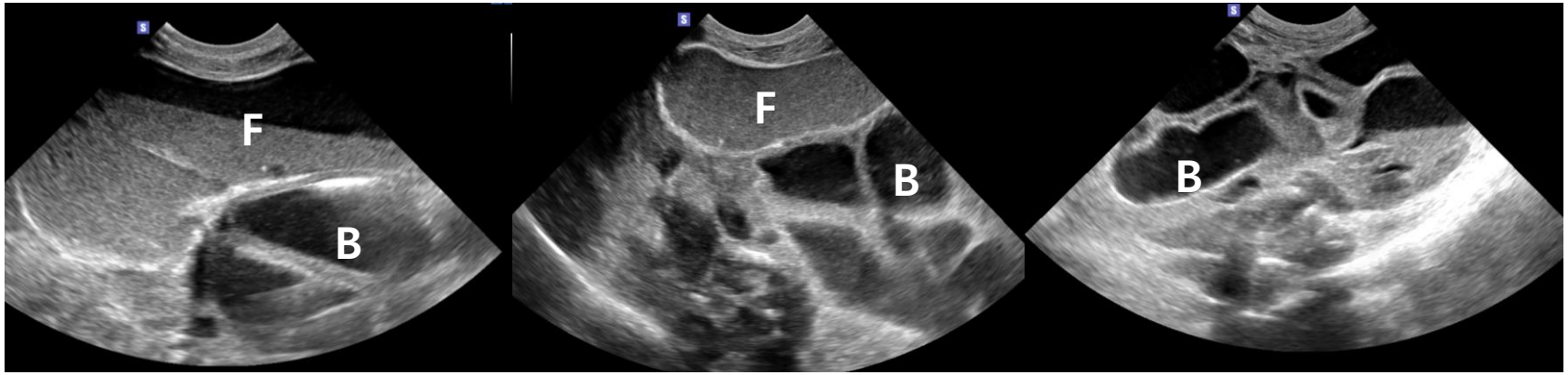

F: fluid , B: bowel

CASE 11

11. What is your diagnosis?

① Duplication cyst
② Duodenal atresia
③ Meconium peritonitis **Answer (1 point)**
④ Necrotizing enterocolitis
⑤ Hypertrophic pyloric stenosis

CASE 11

Meconium peritonitis

- Meconium pseudocyst : collection of meconium localized by fibrous membrane
- Radiography
  - Abdominal soft tissue mass with rim, intense Ca++
  - Linear, curvilinear or punctate Ca++ along peritoneum
  - Ascites and dilatated small bowel d/t obstruction (about 25%)
- USG (pre/post-natal)
  - Hyperechoic punctate, linear echogenic foci ± shadowing
  - Prenatal USG more sensitive than postnatal radiograph
  - Cystic mass ± wall nodularity, Ca++
  - Ascites, complex fluid, very suggestive

CASE 12

- 13/M
- Painless hematuria

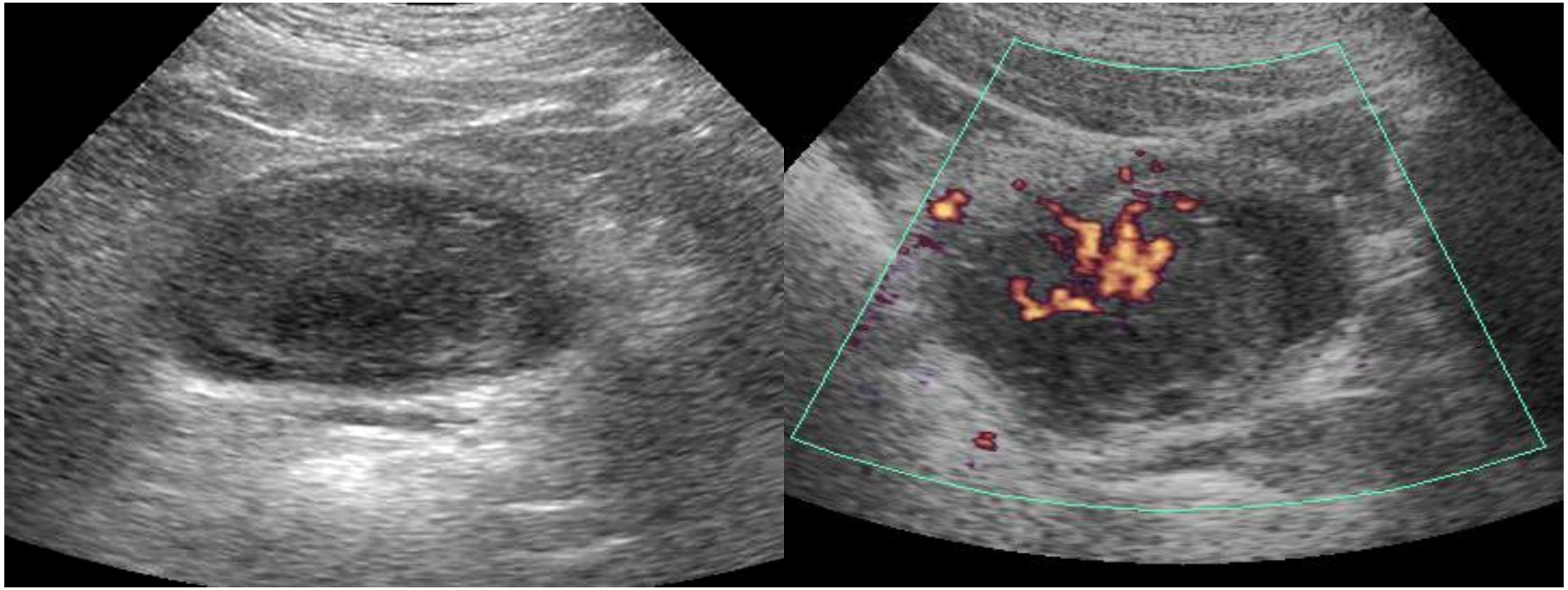

Bladder mass on US

CASE 12

12. What is your diagnosis?

① Papilloma
② Cystitis cystica
③ Inflammatory myoblastic tumor **Answer (1 point)**
④ Transitional cell carcinoma
⑤ Papillary urothelial neoplasm of low malignant potential

CASE 12

Inflammatory Myoblastic Tumor

- A nonneoplastic proliferation of myofibroblastic spindle cells and inflammatory cells with myxoid components
- Male predominance
- Young adults and painless gross hematuria

Radiologic Findings

- Usually as a single ulcerated, bleeding polypoid bladder masses, ringlike enhancement
- Indistinguishable from malignant mesenchymal bladder tumor

(AJR 2008; 191:1255-1262)